



Amba MCZ, ID #5385

Procedure Report

Patient Information

Amba 5385
Tiger Siberian
F/I 7 yrs

Owner information

Milwaukee County Zoo
(414) 256-5441
Drs. Wallace And Clyde

Procedure Information

Laparoscopy and Upper GI Endoscopy
Performed at: Milwaukee County Zoo

August 11, 2010

Indications: Icterus, anorexia, recurrent GI signs

Equipment: 5 mm 30° telescope, 5 mm hepatic biopsy cup

Ports: Two, 5mm, cranial midline

Position: Dorsal recumbency

Biopsies: Hepatic, five 5 mm

Complications: none

Endoscopic Findings:

It was elected to perform laparoscopy restricted to dorsal recumbency and limit laparoscopic biopsy collection to hepatic samples and, subsequently, collect gastric and duodenal mucosal biopsies via upper GI flexible endoscopy.

The peritoneal cavity was insufflated with CO₂ via a Veress needle placed through an incision two cm cranial to the umbilicus, on the midline. A 5 mm port was placed through this site. A second 5 mm port was placed ~8 cm cranial and to the right of midline.

Examination of the peritoneal cavity revealed a mild, icteric, serous effusion was present. The bowel, as viewed through the omentum, appeared normal in color and distribution. The serosal surface of the stomach appeared normal as well. The spleen was normal in size and shape, but was mottled with dark and hyperemic areas, and the surface was irregularly clouded with opaque to white, plaque-like coating. There were white nodules on the margin near the tail. These findings may be age-related change, but could be the result of protein deposition secondary to peritoneal inflammation and effusion.

The liver lobes were smooth with blunt margins. They were pale and icteric in color with a distinct nutmeg pattern. There were no masses or other significant abnormalities found, except for a fusion of the caudolateral tip of the right cranial lobe to the craniolateral aspect of the right caudal lobe. This may be normal architecture for Amba (tigers?) as there was no inflammation or fibrosis apparent at the site. The gall bladder passed from centrally to the right lateral extent of the liver, between the two right lobes, which may also be normal architecture for tigers. The gall bladder appeared to have venous and lymphatic congestion of the serosal surface – lymphatic vessels appeared distended with clear, icteric fluid. The surface appeared dark and the bladder was soft and flaccid. No masses or marked tortuosity of the bile duct were appreciated. There was superficial, opaque, possibly fibronous, deposition on the surface of the liver beneath the bile duct, in the fossa of the gall bladder – an indication of possible inflammatory process in

Procedure Report

the area. It was elected not to collect samples of the peritoneal effusion, gall, or spleen via fine needle aspiration.

Five hepatic biopsies were collected with a 5 mm biopsy cup, from sites in multiple lobes. Clotting at the sites appeared normal and there was no significant hemorrhage apparent at the time of closure. Three biopsy samples were preserved in formalin for histopathology, one was placed in sterile saline for culture, and one sample was preserved for freezing.

The abdominal wall was closed with 0 PDS, as was the subcutaneous tissue. The skin was apposed with 2-0 PDS subcuticularly and the incisions sealed with tissue glue.

Upper GI endoscopy was performed. There was tenacious, clear mucus throughout the esophagus, but the mucosa appeared normal. Heavy mucus was also present within the stomach, as was ingesta. Complete examination of the stomach was hampered by the ingesta and technical difficulties. Several small, blue, soft foreign bodies were present amongst the ingesta and were determined to likely be antibiotic capsules. The gastric mucosa appeared normal, though pale. There were a few, focal, hyperemic areas, but no significant ulcers were observed. The pylorus was transited, but the scope could not be passed very far into the duodenum. The duodenal mucosa may have been more smooth and pale than is typical, but there were no dramatic abnormalities appreciated. Multiple biopsies of the duodenal mucosa were collected, some passing the biopsy instrument far into the duodenum. Multiple gastric biopsies, from pyloric antrum and gastric body, were collected as well. The stomach was suctioned of gas and Amba was recovered.

Videos:

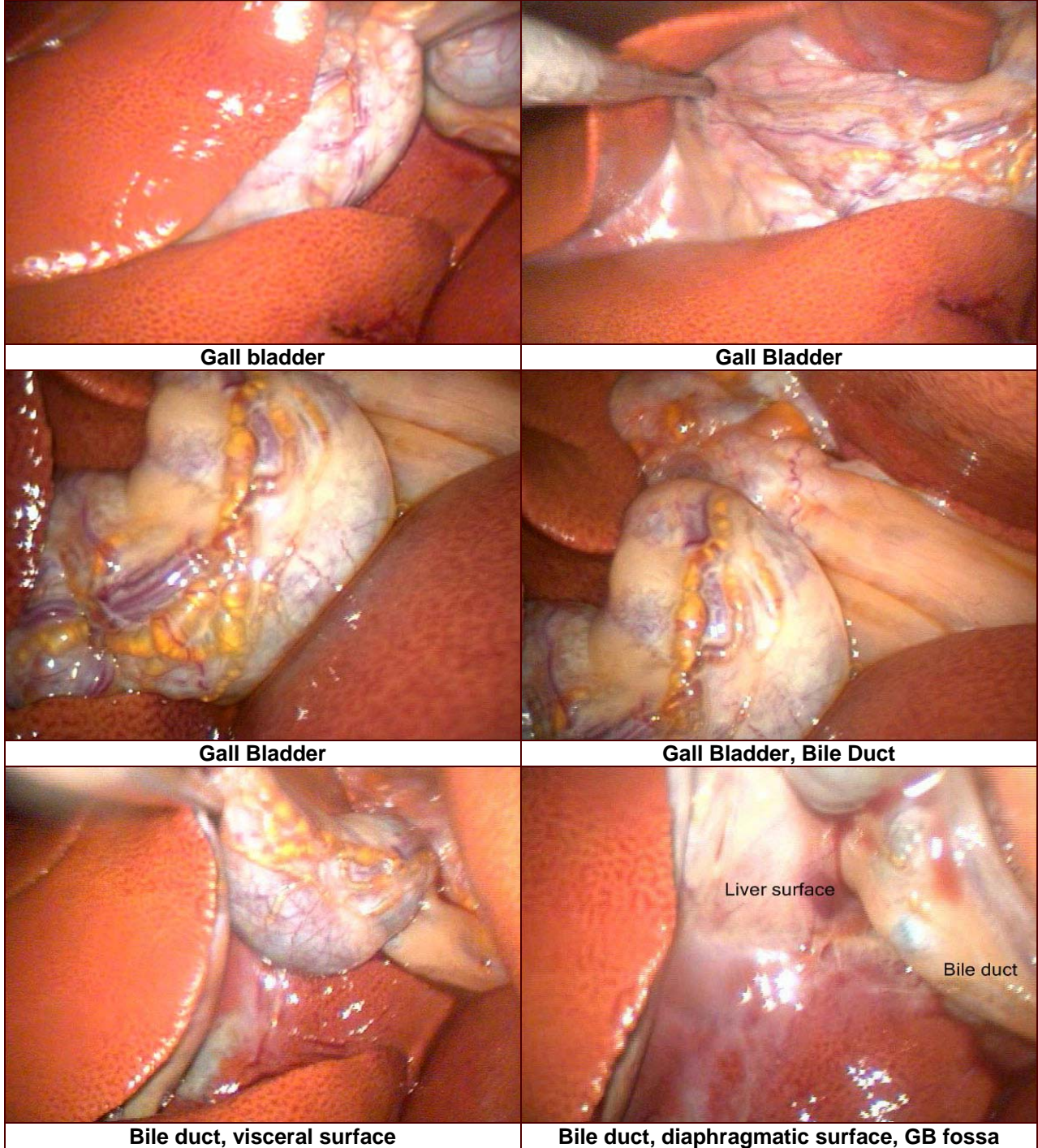
Spleen and Effusion	Small Intestines
Biliary System	Hepatic Biopsies
Gastroscopy	Duodenal Biopsy

Procedure Report

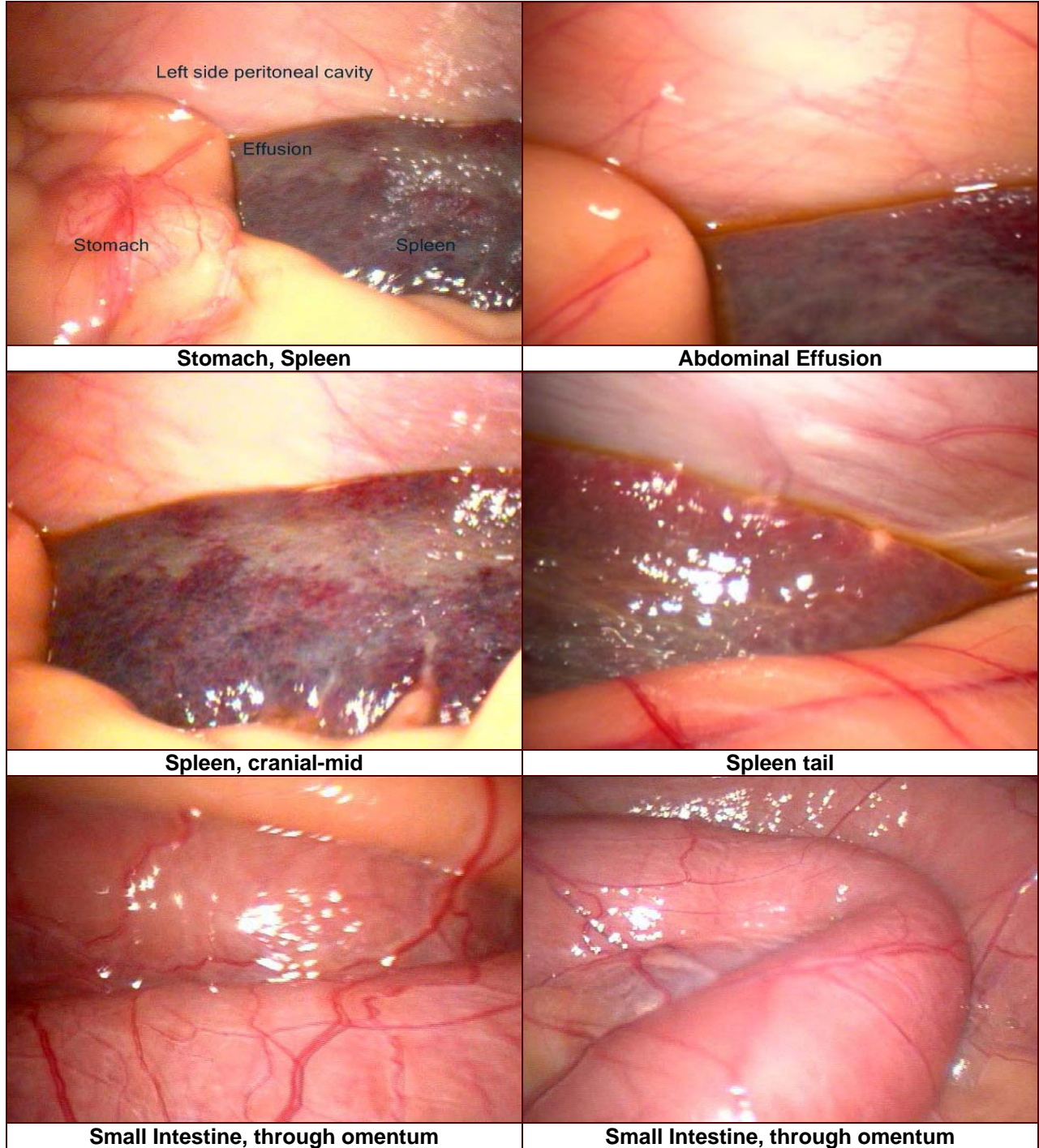Images:



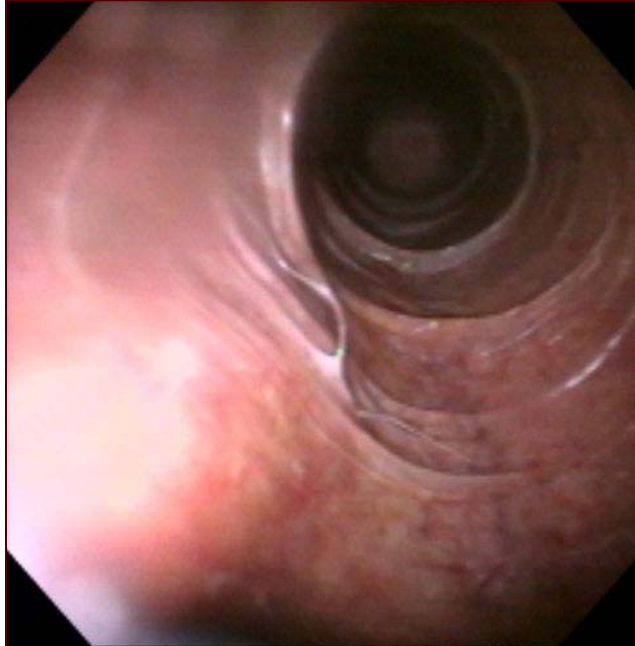
Procedure Report



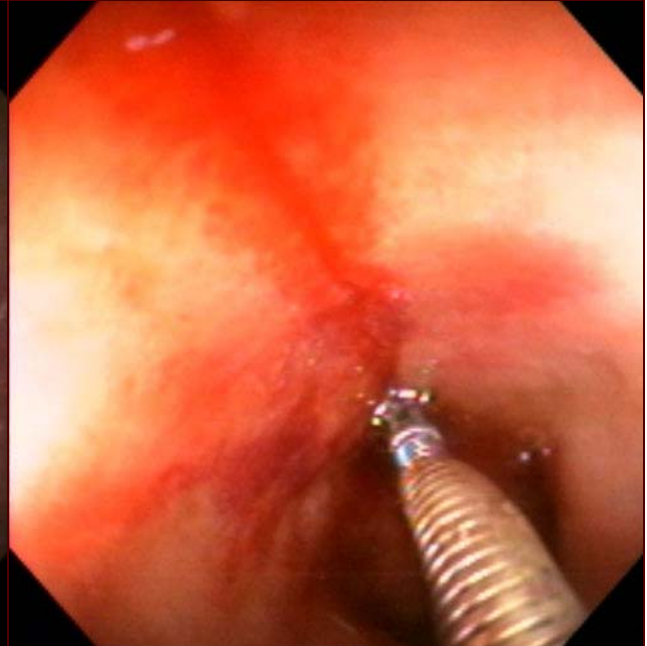
Procedure Report



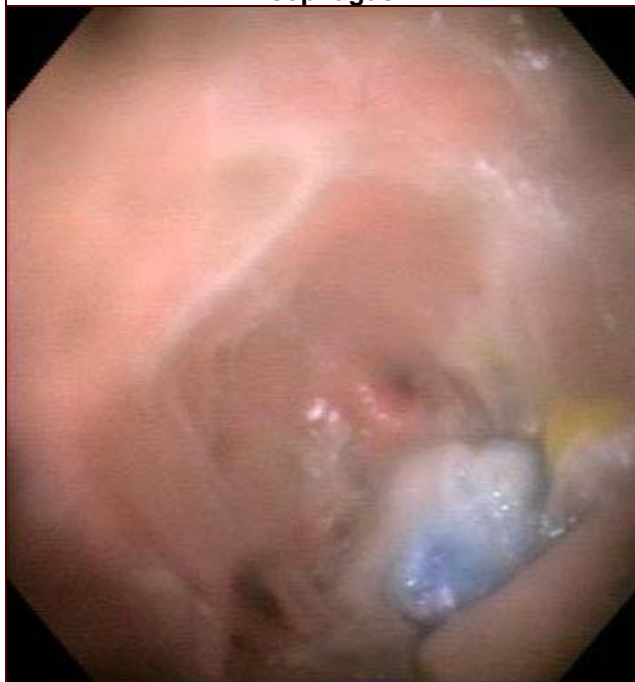Procedure Report



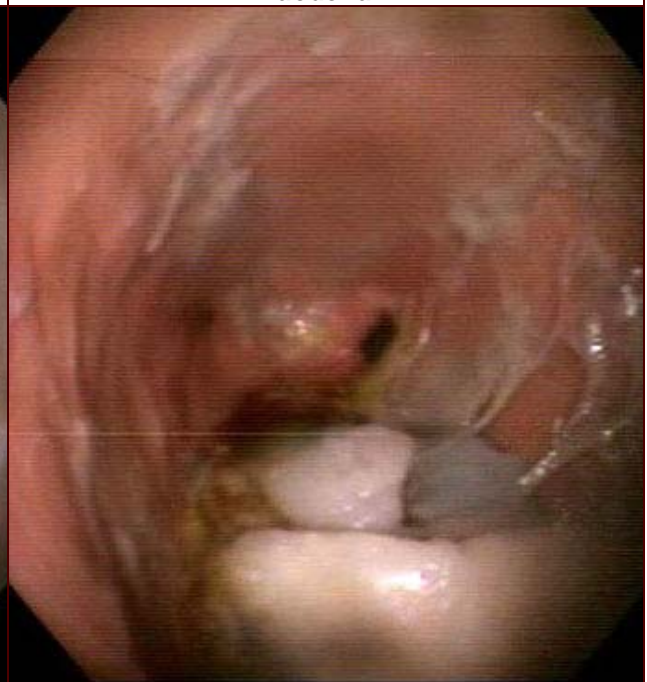Esophagus



Duodenum



Pyloric antrum, FBs



Gastric body, Pyloric antrum