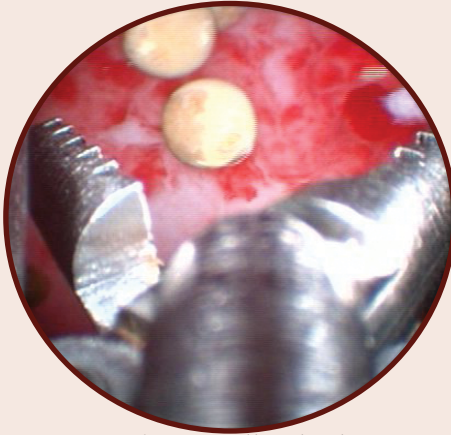


Cystoscopy

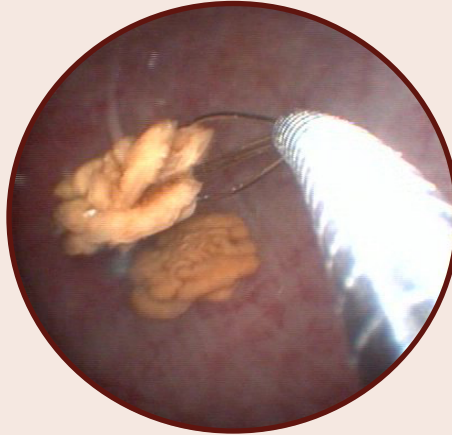
Minimally Invasive Approaches to Lower Urinary Tract Disease

Cystoscopy and laparoscope-assisted cystotomy allow for evaluation, biopsy and sometimes resolution of bladder and urethral problems without traditional surgical approaches and with enhanced visualization allowing discovery of disease and calculi that may be too small to see or in areas too difficult to access by traditional means. VLS has the capability to perform **urethroscopy** and **cystoscopy** in female cats and dogs, or male cats post perineal urethrostomy, and urethroscopy of the distal urethra in male dogs.

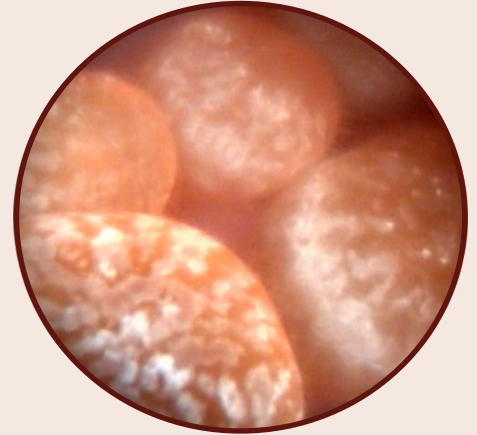Laparoscope-assisted cystotomy can be performed in all animals by using a small incision in the abdomen for access to the bladder for large stone removal or when the urethra is too narrow or long.



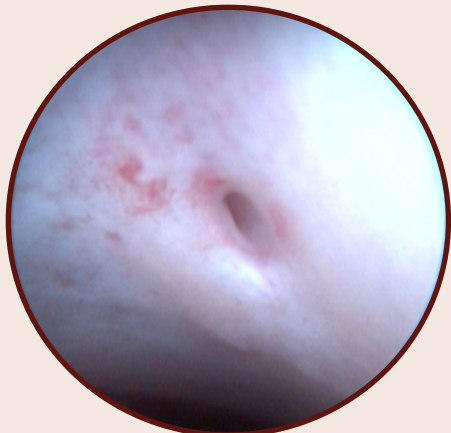Grasping small calculus



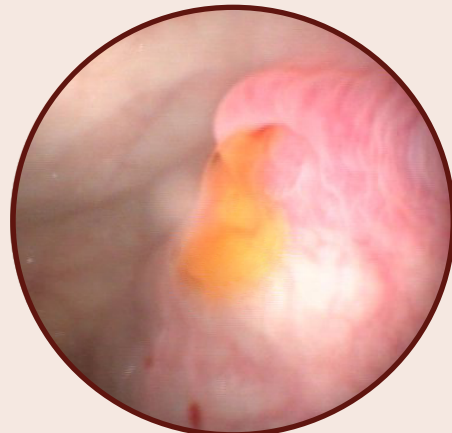
Grasping calculus with wire basket



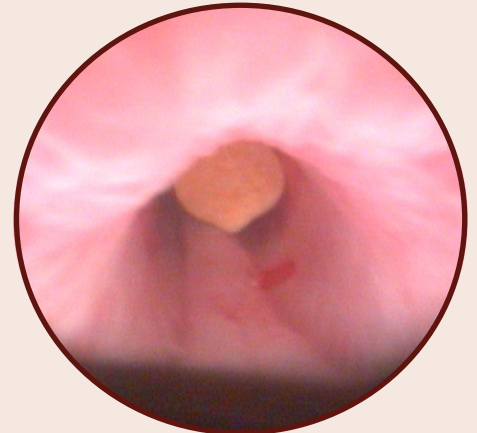
Multiple cystic calculi in a cat



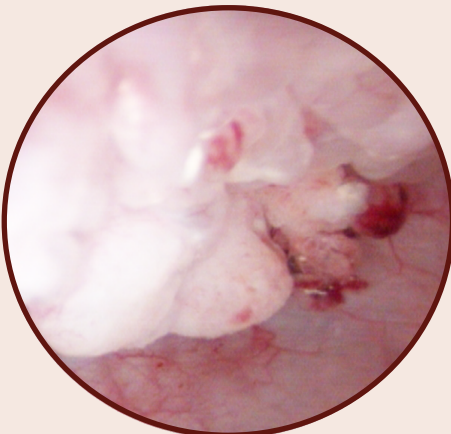
Opening of right ureter



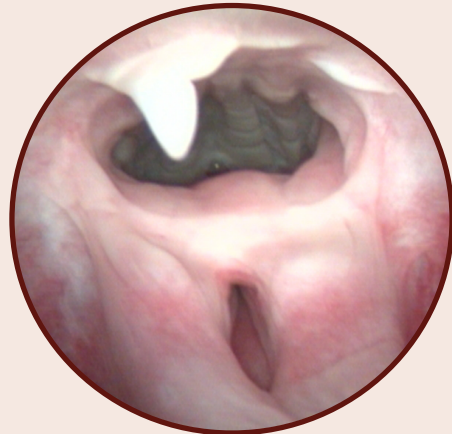Urine flow from ureteral orifice



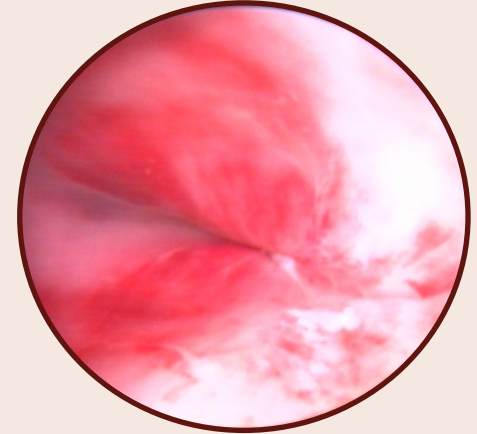
Calculus in male cat's urethra



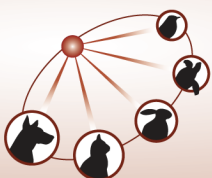
Transitional Cell Carcinoma



Hymenal remnant



Partial stricture of male dog's urethra



Veterinary Laparoscopic Services, LLC

Choose for your pet as you would choose for yourself.

Keith A. Gunby, DVM
www.vetlap.com

(608) 438-4172
VLS@vetlap.com